

Neuromyelitis optica spectrum disorder – case report

Schorzenie z kręgu neuromyelitis optica – opis przypadku

Grażyna Ściegienna-Zdeb¹, Marta Mierzwa-Molenda²

¹Department of Rehabilitation, Regional Hospital, Kielce, Poland

Head of the Department: Grażyna Ściegienna-Zdeb MD

²Doctoral Studies, Faculty of Medicine and Health Sciences, Jan Kochanowski University, Kielce, Poland

Head of the Faculty: Prof. Stanisław Głuszek MD, PhD

Medical Studies/Studia Medyczne 2016; 32 (1): 45–48

DOI: 10.5114/ms.2016.58805

Key words: neuromyelitis optica, demyelination, spinal cord, spastic paresis, aquaporin 4.

Słowa kluczowe: *neuromyelitis optica*, demielinizacja, rdzeń kręgowy, porażenie spastyczne, akwaporyna 4.

Abstract

The study presents the case of a 45-year-old woman with a rare case of Devic's disease (neuromyelitis optica – NMO) admitted to the Department of Rehabilitation in Kielce. In her first interview she stated that for 2 years she had been experiencing an embracing pain in her torso, hemifacial pain and temporary deterioration in her lower limbs with sensory disorders of the body. Magnetic resonance imaging of the thoracic spine revealed a lesion of probably a demyelinating nature as well as a positive test for antibodies against aquaporin 4, for NMO identification. Due to relapse of the disease the patient was treated several times in the Department of Neurology, initially with plasmapheresis, methylprednisolone and then double immunosuppressive rituximab. At that time, the neurological condition of the patient was changing. The article presents the medical history, clinical course and treatment.

Streszczenie

W pracy przedstawiono przypadek rzadkiej choroby Devica (*neuromyelitis optica* – NMO) u 45-letniej pacjentki przyjętej do Kliniki Rehabilitacji w Kielcach. W wywiadzie od ok. 2 lat pojawiały się bóle opasujące tułowia, połowiczny ból twarzy, okresowe pogorszenie sprawności kończyn dolnych z zaburzeniami czucia. W badaniu metodą rezonansu magnetycznego kręgosłupa piersiowego stwierdzono zmianę, prawdopodobnie o charakterze demielinizacyjnym, oraz potwierdzono obecność przeciwciał przeciwko akwaporynie 4, które są wykorzystywane do rozpoznawania NMO. Z powodu zaostrzeń choroby pacjentka była kilkakrotnie leczona w Klinice Neurologicznej, początkowo plazmaferezami, metyloprednizolem, następnie dwukrotnie immunosupresyjnie rituksymabem. W tym czasie stan neurologiczny pacjentki ulegał zmianie. W pracy przedstawiono wywiad chorobowy, przebieg kliniczny schorzenia i leczenie.

Introduction

Neuromyelitis optica (NMO), also known as Devic's disease or Devic's syndrome, and neuromyelitis optica spectrum disorders (NMOSD) are severe demyelinating diseases of the central nervous system (CNS), with a predilection for optic nerves and the spinal cord [1–4]. Clinical features, radiological data, diagnostic tests and immunopathology help to distinguish NMO from multiple sclerosis (MS). The clinical course is characterized by recurrent inflammation of the retrobulbar optic nerve and recurrent transverse myelitis. The disease is not always limited to the optic nerves and the spinal cord. The main radiological criteria for NMO are: longitudinal involvement of the cord affecting more than 3 continuous vertebral segments and in combination with a cranial magnetic resonance imaging (MRI) scan normally does not

meet the radiological criteria for MS [1]. In the serum of patients with NMO and NMOSD the presence of specific IgG antibodies, which have been classified as NMO-IgG, has been identified. The protein aquaporin 4 is an antigen recognized by NMO-IgG [1, 2, 4–7]. Immunosuppressive therapy is used in the treatment of NMO and NMOSD. Treatment should be initiated as soon as possible. Azathioprine and rituximab are recommended as first-line drugs. Other immunosuppressive drugs – methotrexate, mitoxantrone, mycophenolate mofetil – are used in the subsequent disease relapse [5]. Throughout the whole period of the disease, rehabilitation should be applied. The prognosis for the disease in the case of the relapsing one is not favorable. The disease causes loss of vision and an inability to walk independently. There is a better prognosis for monophasic NMO, which is very rare [7].

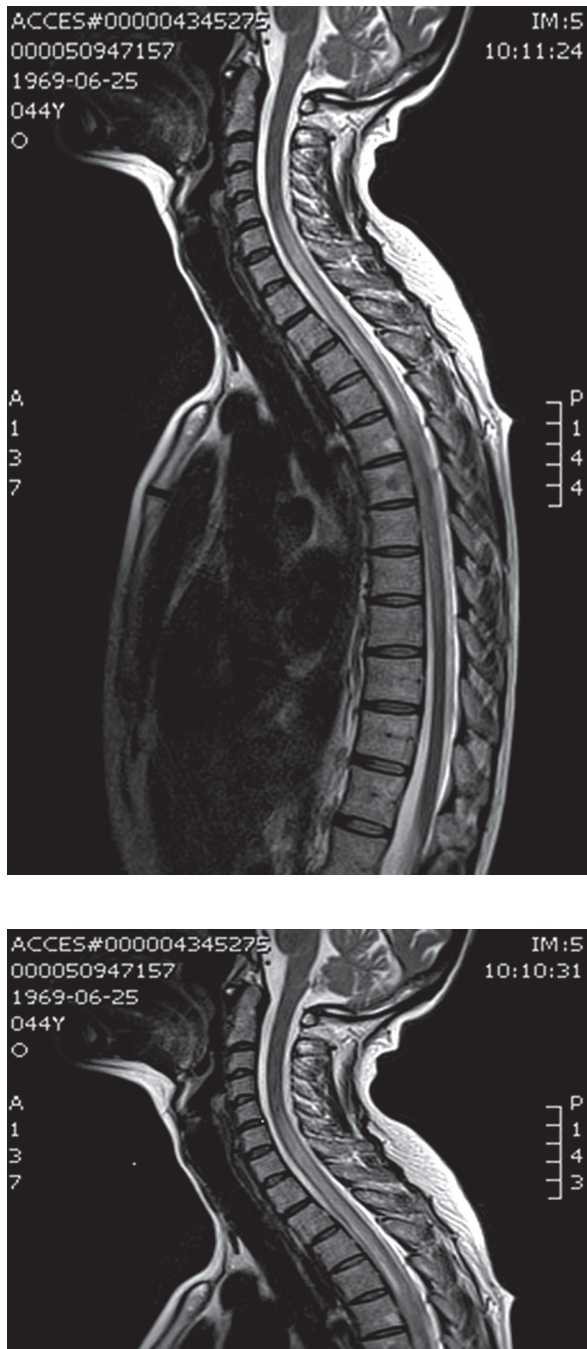


Figure 1. Magnetic resonance imaging to the cervical and thoracic spine of the patient E.K. with spinal cord lesion (presented with patient's agreement)

Case report

The aim of the study is to present the case of a 45-year-old woman with a rare case of NMOSD. In November 2014 a 45-year-old woman was immediately admitted to the Department of Rehabilitation for therapy because of a spastic paralysis of the lower limbs. In

the medical interview the patient reported an embracing, abdominal pain, for approximately 2 years. For this reason, she had been treated at the Surgical Department twice and was diagnosed with: esophageal hernia, and gastric and esophageal erosion. Gallstones were ruled out after investigation. In April 2014, due to an embracing trunk and global pain with palpitations, the patient was admitted to the Gastroenterology Department and after a medical interview was diagnosed with: Th5 vertebral angioma, hyperalgesia below Th6, CNS demyelination, septal aneurysm, depressive disorders with symptoms of somatization, esophageal hernia, esophagitis, and stomach erosion. In March 2014 the patient was admitted to the Neurology Department in Kielce twice with the diagnosis: hyperesthesia below Th6, Th5 vertebral angioma, CNS demyelination, depressive disorders. Magnetic resonance imaging of the thoracic spine with contrast showed a longitudinal lesion from C6 to Th9, which intensified after the contrast agent was added, probably of a demyelinating character (Figure 1).

Additional tests were performed and therefore neuroinfection was excluded (cerebrospinal fluid without evidence of neuroinfection in the general test, absence of antibodies against Lyme disease), cerebrum demyelinating process (MRI with contrast: single, probably vascular change at the base of the right frontal lobe, negative test of cerebrospinal fluid core towards oligoclonal bands) and optic nerves (evoked visual potentials – normal results), systemic disease (cANCA and pANCA antibodies and ANA – negative), porphyria (24-hour urine measurement with porphobilinogen levels within the norm). Positivity for antibodies against aquaporin 4 from serum of 1: 160 (n 1: < 10) was found. In June 2014 the patient was treated at the Neurology Department Public Central Clinical Hospital (IPCCH) in Warsaw, where, due to the clinical course of the disease and further tests, NMO spectrum disorder (longitudinally extensive transverse myelitis – LETM) was diagnosed. During this hospitalization, there was a disease relapse. Clinical manifestations resembling a spinal cord injury suddenly appeared: lower limbs (LL) spastic plegia, lack of surface sensation from Th7 to L1 and weakening of sensation below this area, lack of sense of vibration and of LL alignment, urination and defecation control failure. The patient was classified for treatment with plasmapheresis, a total of 15 200 ml of plasma was replaced, then she was given a total of 7.0 g of intravenous methylprednisolone, which resulted in a significant improvement in her neurological status. After intravenous corticosteroid treatment, leucopenia and increased activity of liver transaminases and γ -glutamyl transpeptidase (GGTP) were detected in control blood tests. Treatment with oral corticosteroids (Methylprednisone 32 mg/day) was also added. Because head and neck MRI showed a right parotid tumor, immunosuppressive therapy

was not included until the nature of the tumor was known. The patient was transferred to the Comprehensive Rehabilitation Center in Konstancin Jeziorna with further recommendations, where comprehensive rehabilitation was carried out, improving the patient's functional state, which allowed independent walking for longer distances using a walker. During the patient's hospitalization, low mood, anxiety, and complaints of recurring severe pains of the trunk were reported. The antidepressant treatment was modified, the dose of gabapentin was increased, and the patient was transferred again to the Department of Neurology SPCSK in Warsaw. During hospitalization abdominal pain occurred, which the patient associated with the beginning of orally administered methylprednisolone 32 mg/day. After reduction of the methylprednisolone dose to 16 mg/day the pain was reduced. In connection with a suspected exacerbation of erosive gastritis as the cause of pain intensity, methylprednisolone was withdrawn and some improvement was achieved. Gastroscopy confirmed the presence of erosions of the gastric mucosa, as had been previously detected in gastroscopy in September 2013. Cervical and thoracic spine control with MRI contrast agents was performed, showing significant regression of demyelination of the spinal cord. Plasmapheresis treatment proved very effective, and therefore such treatment was applied again. The functional state improved: the patient was able to move independently for a distance of approximately 100 m. The patient was transferred to the Department of Otolaryngology to remove the right salivary glands and to identify the tumor character ultimately as a condition for immunosuppressive therapy application. On 1st Sept 2014 right side parotidectomy was executed (histopathology: basal cell adenoma) in the Clinic of Otolaryngology in Warsaw. During the hospitalization an acute relapse occurred and the patient was transferred to the Department of Neurology IPCCH in Warsaw. Upon admission on 16th Sept 2014 there was massive spastic LL paresis with pyramidal symptoms, hypoalgesic level of Th3, vibration sense disorder, massive alignment sensory disturbances in LL, and neurogenic bladder. The patient was treated with rituximab twice. When discharged on 14th Nov 2014 the patient still had massive LL paralysis with hypertonus and excessive reflexes, bilateral Babinski reflex, hypoesthesia below Th8, disturbed sensation of LL alignment and vibration, and neurogenic bladder. The patient's activity level was as follows: active sitting, requires assistance when transferred onto the wheelchair – Expanded Disability Status Scale (EDSS) 7.5.

In Nov 2014 the patient E.K. diagnosed with Devic's syndrome was admitted to the Rehabilitation Clinic of the Regional Hospital in Kielce. Physical examination: the patient cannot function independently, active merely within wheelchair, requires assistance when transferred to bed, provided with cath-

eter, Barthel scale 15, Rankin scale 3, EDSS scale 7.5. Neurological examination: hypoalgesic level below Th4. Absence of: abdominal reflexes and vibration sensation. Symptoms of spastic paralysis of the LL, muscle strength according to Lovett scale: 3 in right LL, 2 in left LL. Muscle tension according to Ashworth scale: 2 in right LL, 3 in left LL, tendon reflexes in LL. Babinski reflex, Rossolimo reflex bilaterally positive, neurogenic bladder. Psychological examination: secondary reduction of memory function and visual motor coordination, personal adaptation disorders, mood disturbance – high emotional dysregulation with features of depression. The plan of physiotherapy: proprioceptive neuromuscular facilitation (PNF) therapy, active verticalization, learning self-sufficiency in a wheelchair, mobilization of different respiration paths, joints range of motion maintenance, pathological tension reduction, assisted locomotion in the parallel bars with ankle foot orthosis (AFO), classic massage of lower limbs, hydromassage of upper limbs, occupational therapy.

The therapy was conducted in the morning, when cooperation with the patient was the best in terms of muscular strength and coordination. Therapy during the following days of treatment was adjusted to the current functional condition of the patient by using a small number of repetitions and high frequency of intervals (to avoid the patient's fatigue). The full treatment plan was carried out for 3 days. On the 4th hospitalization day the patient complained about major, abdominal embracing pain, which was confirmed by neurological deterioration. Paralysis of the lower limbs rapidly developed, which could have meant another acute attack. For this reason, the patient was transferred to the Department of Neurology in Warsaw in order to undergo further clinical treatment. Rehabilitation was postponed for the duration of treatment in the Department of Neurology in Warsaw and the patient was given 8 g of Methylprednisone. After a period of exacerbation of symptoms the patient was again admitted to the Department of Rehabilitation in Kielce, where the treatment was continued. As a result, the patient showed improvement: self-sufficiency in a wheelchair, walking with therapist assistance with a walker at the distance of 20 m. EDSS 7. Barthel 25.

Discussion

Relapses of disease, prevention of NMO exacerbation and symptomatic therapy of residual symptoms are taken into consideration during NMO and NMOSD treatment [5]. Acute attacks of disease, such as progressive paresis and paralysis of the lower limbs and bladder disorders, cause activity limitations. The patient is disabled and forced to use a wheelchair. During relapses corticosteroid therapy is used (methylprednisolone is used as in classical MS). Plasma exchange is applied especially when response to treat-

ment with corticosteroids does not occur or when there are severe relapses of disease [3–5, 7, 8]. The first-line therapy is azathioprine in combination with prednisolone or alternatively the monoclonal antibody rituximab (directed against the CD20 antigen on the surface of B lymphocytes). Pharmacological therapy of NMO should be initiated as soon as possible. During the time of relapse symptoms such as limited activity of the patient (correlation with EDSS) and low emotional status are observed. Rehabilitation should be continued in the period of remission in which the patient presents paralysis regression, therapy has to be specified and his functional abilities increased. The disease symptoms (such as spasticity or sphincters dysfunction) are carried out as in classical MS treatment [3–5, 7–10].

Conclusions

This case is an illustration of a long diagnostic process in this rare form of disease. The study presents the possibilities of treatment in a severe case, based on a multidisciplinary clinical team. The most important problem of NMO patients is limited activity of daily living (ADL), so one goal of this article was also to present the important role of rehabilitation, as a support, in the independent character of the disease.

Conflict of interest

The authors declare no conflict of interest.

References

1. Wingerchuk DM. Neuromyelitis optica. *Int MS J* 2006; 13: 42-50.
2. Jurewicz A. Choroba Devica – nowe poglądy i nowe metody diagnostyczne. *Pol Przegl Neurol* 2010; 6 Suppl. A: 28-9.
3. Rowland LP, Pedley TA. *Neurology Merrit. Vol. 3.* Kwieciński H, Kamińska AM (eds. Polish ed.). Elsevier U&P, Wrocław 2012.
4. Jacob A, Matiello M, Wingerchuk DM, Lucchinetti CF, Pittock SJ, Weinshenker BG. Neuromyelitis optica: changing concepts. *J Neuroimmunol* 2007; 187: 126-38.
5. Trebst C, Jarius S, Berthele A, Paul F, Schippling S, Wildemann B, Borisow N, Kleiter I, Aktas O, Kümpfel T; Update on diagnosis and treatment of neuromyelitis optica: Recommendations of Neuromyelitis Optica Study Group (NEMOS). *J Neurol* 2014; 261: 82-9.
6. Jordan B, Eger K, Kornhuber ME, Zierz S. Neuromyelitis optica: a separate disease entity associated with aquaporin-4 antibodies. *Fortschr Neurol Psychiatr* 2008; 76: 21-7.
7. Zakrzewska-Pniewska B. Standardy diagnostyki i leczenia zapalenia nerwów wzrokowych i rdzenia Devica. *Neurologia po Dyplomie* 2011; 6: 14-21.
8. Kimbrough DJ, Fujihara K, Jacob A, Lana-Peixoto MA, Leite MI, Levy M, Marignier R, Nakashima I, Palace J, de Seze J, Stuve O, Tenenbaum SN, Traboulsee A, Waubant E, Weinshenker BG, Wingerchuk DM; GJCFC-CC&BR. Treatment of neuromyelitis optica: review and recommendations. *Mult Scler Relat Disorder* 2012; 1: 180-7.
9. Kurtzke J. Rating neurologic impairment in multiple sclerosis. An expanded disability status scale (EDSS). *J Neurol* 1983; 33: 1444-52.
10. Łuszczynska A, Kuliński W. Physiotherapy in multiple sclerosis. *Medical Studies* 2015; 31: 168-77.

Address for correspondence

Grażyna Ściegienna-Zdeb MD
Department of Rehabilitation
Regional Hospital
ul. Kościuszki 3, 25-310 Kielce, Poland
Phone: +48 41 340 36 20
E-mail: gzdeb8@gmail.com